

RESEARCH ARTICLE

Early Outcomes of Image-Guided Hypofractionated Volumetric Modulated Arc Radiotherapy (IG-HyVMAT) in Dogs with Non-Lymphomatous Nasal Tumors (NLNT)

Onur ÜLGENALP¹ , Emine Esma ÇERKEZ¹ , Vildan ALPAN¹ , Ezgi OYMAK² ,
Fatma Eser ÖZGENCİL¹ , Özgecan KULEYİNOĞLU^{1(*)} , Alper DEMİRUTKU³ ,
Adeyşe Perran GÖKÇE¹ , Yasemin ATAGUN^{2,4} , Uğur SELEK^{2,4} 

¹ VetAmerikan Animal Hospital, TR-34406 İstanbul-TÜRKİYE

² VKV American Hospital, Department of Radiation Oncology, TR-34365 İstanbul - TÜRKİYE

³ Faculty of Veterinary Medicine, University of Istanbul Cerrahpaşa, Department of Surgery, TR-34320 İstanbul - TÜRKİYE

⁴ School of Medicine, Koç University, Department of Radiation Oncology, TR-34450 İstanbul - TÜRKİYE



(*) **Corresponding author:**

Özgecan Kuleyinoğlu
Phone: +90 534 411 1386
E-mail: ozgecank@vetamerikan.org

How to cite this article?

Ülgenalp O, Çerkez EE, Alpan V, Oymak E, Özgencil FE, Kuleyinoğlu Ö, Demirutku A, Gökçe AP, Atagun Y, Selek U: Early Outcomes of Image-Guided Hypofractionated Volumetric Modulated Arc Radiotherapy (IG-HyVMAT) in Dogs with Non-Lymphomatous Nasal Tumors (NLNT). *Kafkas Univ Vet Fak Derg*, 32 (2): 281-290, 2026.
DOI: 10.9775/kvfd.2026.36051

Article ID: KVFD-2026-36051

Received: 06.01.2026

Accepted: 20.04.2026

Published Online: 26.04.2026

Abstract

Radiotherapy is a cornerstone in the management of canine non-lymphomatous nasal tumors (NLNT), providing both palliative benefit and local tumor control. Image-Guided Hypofractionated Volumetric Modulated Arc Radiotherapy (IG-HyVMAT) has recently emerged as a promising treatment modality for canine sinonasal tumors; however, data regarding tumor control, radiation-associated morbidity, and treatment outcomes across specific tumor histotypes remain limited. This retrospective study evaluated treatment response as well as early and late toxicities in 12 dogs with NLNT treated using IG-HyVMAT or IG-HyVMAT with a simultaneous integrated boost (SIB) protocol. Tumors were staged using a modified veterinary radiotherapy staging system, and treatment-related toxicities were assessed according to the Veterinary Radiation Therapy Oncology Group (VROG) criteria. IG-HyVMAT, most commonly delivered in combination with SIB, was prescribed at doses ranging from 25 to 40 Gy. The treatment protocols were well tolerated and associated with minimal acute toxicity. Clinical signs such as dyspnea and nasal congestion were identified as important prognostic indicators for survival in dogs with NLNT. The observed overall survival time (OST) and progression-free survival time (PFST), together with the low incidence of acute adverse effects, suggest that the SIB approach may offer potential clinical benefits, particularly in cases requiring palliative treatment. Overall, the findings of this study indicate that IG-HyVMAT, frequently applied with SIB, may provide meaningful survival advantages in dogs with NLNT while maintaining an acceptable toxicity profile. Nevertheless, further studies incorporating more advanced dose-optimization strategies for adjacent critical organs are warranted.

Keywords: Dog, IG-HyVMAT, IMRT, Non-lymphomatous nasal tumor, Radiotherapy, Toxicity, VMAT

INTRODUCTION

Non-lymphomatous sinonasal tumors (NLNTs) in dogs are predominantly of epithelial or mesenchymal origin and are characterized by aggressive local invasion. These tumors typically extend from the rostral nasal cavity toward the frontal sinuses and may progress intracranially, including invasion of adjacent bony structures such as the cribriform plate^[1]. Due to their locally invasive behavior and anatomically complex location, the treatment of NLNTs remains challenging. Previous studies have demonstrated that chemotherapy, either alone or in combination with surgery, does not provide superior outcomes compared with radiotherapy (RT) in dogs

with NLNT. Consequently, RT has become the primary treatment modality for these tumors and is used with either palliative or curative intent^[2].

Reported survival times following treatment vary considerably. Median survival in untreated dogs is approximately 3.1 months (93 days), while dogs receiving chemotherapy alone may achieve survival times of up to 7.8 months (234 days). In contrast, dogs treated with RT have reported median survival times ranging from 10 to 19 months (300-540 days)^[3,4].

Conventional two-dimensional radiotherapy is associated with limited conformity, often resulting in inadequate dose delivery to the tumor target



while exposing adjacent normal tissues to substantial radiation. In addition to increased toxicity, this limitation frequently prevents the delivery of an adequate dose to the tumor target volume. In contrast, three-dimensional conformal radiotherapy (3D-CRT), although still relatively limited in veterinary medicine, enables improved target delineation through advanced imaging and allows radiation delivery from multiple beam angles. Within this framework, target volumes are defined as the Gross Tumor Volume (GTV), representing macroscopic disease; the Clinical Target Volume (CTV), encompassing potential microscopic tumor extension; and the Planning Target Volume (PTV), which accounts for patient positioning uncertainties and internal motion. Surrounding normal tissues are contoured as Organs at Risk (OARs) to facilitate dose optimization and reduce treatment-related toxicity.

Further advances in conformal radiotherapy have led to the development of intensity-modulated radiotherapy (IMRT) and volumetric modulated arc therapy (VMAT). These techniques represent an evolution in conformal radiotherapy, using inverse planning algorithms to generate complex dose distributions that conform to predefined dose constraints for both target volumes and organs at risk. Within this context, the simultaneous integrated boost (SIB) technique improves dose conformity by enabling the delivery of different dose levels to multiple target volumes within the same treatment course, potentially enhancing local tumor control. In human head and neck oncology, the application of IMRT with SIB has been associated with reduced acute toxicity and improved clinical outcomes compared with earlier radiotherapy techniques [2].

Advances in imaging, immobilization, and image-guided verification systems have further improved treatment accuracy, enabling the adoption of hypofractionated RT protocols that deliver biologically effective doses comparable to or greater than conventional fractionation schedules (typically 1.8-2 Gy per fraction delivered over 25-40 fractions). Hypofractionated regimens used in canine NLNT typically involve higher doses per fraction (5-8 Gy) administered over 5-15 fractions, providing logistical advantages such as shorter treatment duration and fewer anesthetic events [1]. Considering the need for repeated general anesthesia and the associated financial burden in canine RT treatments, hypofractionated protocols are increasingly accepted in appropriately equipped veterinary oncology centers.

Despite these technical advances, the prognosis of dogs with NLNT remains variable. Tumor stage, histologic type, radiation dose, and fractionation schedule play critical roles in determining clinical outcomes. Because studies reporting radiotherapy planning approaches in

dogs with NLNT are relatively scarce, recent research has focused on optimizing dose and fractionation strategies to improve treatment efficacy while minimizing radiation-induced toxicity [1,4-11].

Therefore, the aim of the present study was to evaluate early and late adverse effects in dogs with NLNT treated at our institution using an image-guided hypofractionated VMAT protocol with simultaneous integrated boost (IG-HyVMAT-SIB), and to provide additional data regarding treatment protocol distribution and clinical outcomes in veterinary radiation oncology.

MATERIAL AND METHODS

Ethical Statement

This study protocol was reviewed by the Koç University Local Animal Experiments Ethics Committee (Approval No: 2025.HADYEK.031). An informed consent form was obtained from each animal owner.

Case Selection

A total of twelve dogs diagnosed with non-lymphomatous nasal tumors (NLNT) at the time of presentation were included in the study. Diagnosis was established based on histopathological evaluation and/or computed tomography (CT) findings, and only cases without regional lymph node involvement or distant metastasis were enrolled. The follow-up period, including both surviving and deceased cases, was defined as 15 months (450 days). Previous surgical interventions were not considered as exclusion criteria.

All cases were staged using the modified Adams staging system. According to this system, tumors confined to a single nasal passage, paranasal sinus, or frontal sinus without bone involvement beyond the turbinates were classified as T1. Tumors with bone involvement extending beyond the turbinates but without orbital, subcutaneous, or submucosal mass formation were classified as T2. Tumors showing orbital, nasopharyngeal, subcutaneous, or submucosal involvement were classified as T3. Tumors associated with cribriform plate lysis were classified as T4, whereas tumors demonstrating intracranial extension into brain tissue were classified as T4a [4].

Clinical signs observed at presentation for each dog were recorded (Table 1). Radiation-associated toxicities were assessed according to the Veterinary Radiation Therapy Oncology Group (VROG) scoring system. Toxic effects observed within the first three months following radiotherapy were classified as acute, whereas those developing later were considered late toxicities [12]. Tumor regrowth following an initial regression or progression of residual disease based on post-treatment imaging findings was defined as disease recurrence.

Table 1. Breed-age distribution, common clinical distribution, tumor type, tumor stage, disease-free survival conditions (PFST), survival conditions (ST), acute and chronic side effects of RT, and G-HyVMAT and SIB with IG-HyVMAT administration doses (total dose Gy/fr) were reported in 12 dogs with NLNT

Case	Breed/Age	CCS	T	PFST day	ST day	MAS	ASE /Grade	CSE/Grade	IG-HyVMAT Gy/fr	IG-HyVMAT SIB Gy/fr
N1	GR/12	E, DY, EP, NC	MC	132	150	4	Sk/G3, MM/G0, E/G2	-	30/5	
N2	GR/14	DY, NC	SCC	91	105	1	Sk/G1, MM/G3, E/G1		-	15-25/5
N3	T/8	EP, SN	HMC	440	450 survival	2	Sk/G2, MM/G0, E/G1	Sk/G1, E/G0		30-35/5
N4	GR/13	EP, DY, NC	AC	403	440	2	Sk/G2, MM/G0, E/G2	Sk/G2, E/G2		30-35/5
N5	GR/9	EP, NC	AC	17	40	3	-	-		30-35/5
N6	T/8	DE, EP	SCC	304	450 survival	3	Sk/G2, MM/G2, E/G2	Sk/G1, E/G2		25-35/5
N7	GR/8	DE, EP, NC	SCC	266	450 survival	3	Sk/G3, MM/G0, E/G2	Sk/G1, E/G2		30-35/5
N8	St/11	EP, NC, SN	SCC	207	450 survival	2	Sk/G2, MM/G0, E/G0	Sk/G1, E/G0		35-40/5
N9	T/2	DE	MH	443	450 survival	3	Sk/G1, MM/G0, E/G0	Sk/G0, E/G0	30/5	
N10	LR/13	EP, EX, DE	TCC	320	450 survival	4a	Sk/G1, MM/G0, E/G0	Sk/G2, E/G0	30/10	
N11	T/14	DE, EX	NA	208	450 survival	4	Sk/G0, MM/G0, E/G0	Sk/G0, E/G0	30/5	
N12	GR/14	NC	NA	87	100	3	-	-	18/3	

GR: Golden retriever, **T:** Terrier, **LR:** Labrador retriever, **ST:** Setter, **MCCS:** Most Common Clinical Symptoms, **DE:** Deformity, **DY:** Dyspnea, **EP:** Epistaxis, **NC:** Nasal Congestion, **SN:** Sneeze, **EX:** Exoftalmus, **TT:** Tumor Type, **HMC:** Hemanjiosarcom, **SCC:** Squamos Cell Carcinoma, **AC:** Adenocarcinoma, **MH:** Malignant Histiocytoma, **TCC:** Transitional Cell Carcinoma, **NA:** Undifferentiated Adenocarcinoma, **PFST:** Progression-Free Survival Time/Disease-Free Survival, **ST:** Survival time, **MAS:** Modified Adams Stages, **ASE:** Acute Side Effects, **CSE:** Chronic Side Effects, **G:** Grade, **Sk:** Skin, **MM:** Mucous membrane, **E:** Eye, **IG-HyVMAT D:** Image guided hypofractionated volumetric modulated arc radiotherapy dose, **IG-HyVMAT SIB D:** Image guided hypofractionated volumetric modulated arc radiotherapy with simultaneous integrated boost dose, **Gy:** Total radiation dose, **fr:** Fraction

Treatment Protocol

In the treatment approach, IG-HyVMAT was primarily preferred for more localized lesions and in situations where proximity to critical organs was a concern. The IG-HyVMAT with simultaneous integrated boost (SIB) protocol was applied in cases with substantial gross tumor volume (GTV) where the treatment objective was to achieve improved local palliative control. Doses administered to animals were determined based on the tumor's Adam's staging and proximity to critical organs. Controls were generally provided at 8-10 week intervals.

All simulation and treatment procedures were performed under general anesthesia. Anesthesia was induced with propofol (4-8 mg/kg; Polifarma, Türkiye), followed by endotracheal intubation and maintenance with sevoflurane in 80% oxygen under controlled mechanical

ventilation. Patients were continuously monitored via camera throughout the anesthetic period.

For each treatment session, dogs were positioned and immobilized to ensure reproducible head and body alignment. Immobilization was achieved on the CT simulation table with the patient in sternal recumbency, using a patient-specific molded foam head support, thermoplastic mask, and vacuum cushion (Civco) (Fig. 1). The forelimbs were aligned parallel to the body, the shoulders were positioned symmetrically, and the hind limbs were extended to improve stability. To further reduce variability in head and neck positioning and control the mandibular angle, a patient-specific tongue depressor and maxillary dental bite block were incorporated during thermoplastic mask fabrication.

CT images were acquired from the vertex to the level of the C3 vertebra with a slice thickness of 1 mm. To assist




Fig 1. Head mask that prevents head movement during radiation therapy

with accurate target delineation, magnetic resonance imaging (MRI) scans were co-registered with the planning CT images.

The GTV, CTV, and OARs were contoured by a veterinarian in collaboration with a radiation oncology specialist. The GTV was defined based on CT and MRI findings combined with physical examination results. The CTV was generated by applying a 5 mm expansion to the GTV and subsequently cropped at uninvolved anatomical barriers; the entire nasal cavity and sinuses were included within the CTV.

Treatment planning was performed using the Eclipse™ v16.1 treatment planning system (Varian Medical Systems, Palo Alto, CA) with the Analytical Anisotropic Algorithm (AAA) v16.1.2. In this study, the Planning Target Volume (PTV) was defined as a uniform 3 mm expansion of the CTV in all directions (Fig. 2). All treatment plans utilized VMAT.

Each treatment fraction was delivered under general anesthesia. Prior to irradiation, two-dimensional setup verification was performed in the anteroposterior and right

lateral planes, followed by three-dimensional verification using onboard cone-beam computed tomography (CBCT). Treatment delivery was initiated only after setup confirmation by both a veterinary specialist and a medical physicist. Patient-specific quality assurance was performed using Siemens Varian portal dosimetry.

The decision to apply IG-HyVMAT alone or in combination with SIB was made jointly by the radiation oncology specialist and the veterinarian, considering tumor size, location, proximity to critical structures, and the overall condition of the patient. To avoid prolonging treatment schedules, SIB planning typically involved assigning two different dose levels to the GTV and CTV within the same number of fractions. In cases where SIB was not applied, a single prescription dose was delivered to both target volumes (Fig. 3).

Based on evaluation of imaging findings in cases treated with IG-HyVMAT, the following fractionation schemes were applied: Cases N1, N9, and N11 received a total dose of 30 Gy (30 Gy/5 fractions) delivered over five consecutive treatments; case N10 received 30 Gy (30 Gy/10 fractions) over ten consecutive treatments; and case N12 received 18 Gy (18 Gy/3 fractions) delivered over three consecutive treatments.

In cases treated with IG-HyVMAT with SIB, case N2 received 15 Gy to the CTV and 25 Gy to the GTV in five consecutive fractions. Cases N3, N4, N5, and N7 received 30 Gy to the CTV and 35 Gy to the GTV over five consecutive fractions, whereas case N6 received 25 Gy to the CTV and 35 Gy to the GTV over five consecutive fractions. Case N8 received 35 Gy to the CTV and 40 Gy to the GTV in five consecutive fractions.

Since the eye is the most affected organ during nasal tumor irradiation, the dose delivered to the right lacrimal gland ranged from 4.4 to 29 Gy (mean: 19.78 Gy), while the dose delivered to the left lacrimal gland ranged from 5.3 to 28.6 Gy (mean: 19.15 Gy).

Statistical Analysis

Descriptive statistics were calculated and are presented as mean, standard deviation (SD), median, interquartile

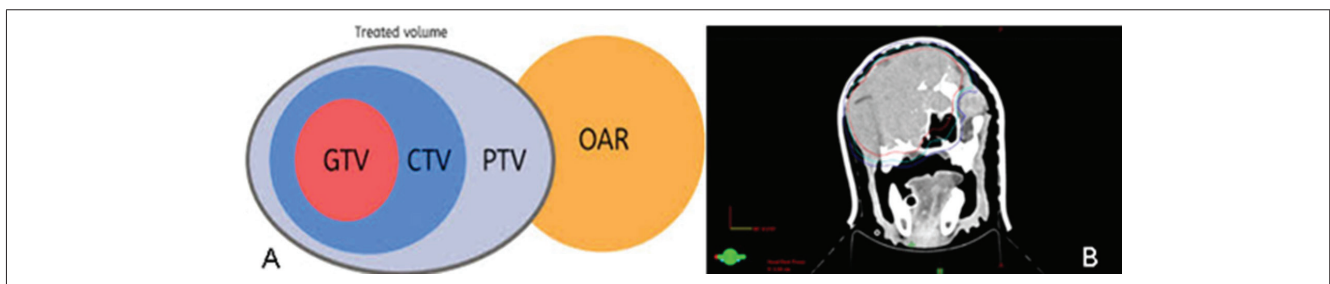


Fig 2. A- Schematic visualization of GTV, CTV, PTV, and QAR determination, B- Planning of GTV (red line), CTV (turquoise line) created with GTV + 5 mm, and PTV (dark blue line) created with CTV + 3 mm in the transverse view

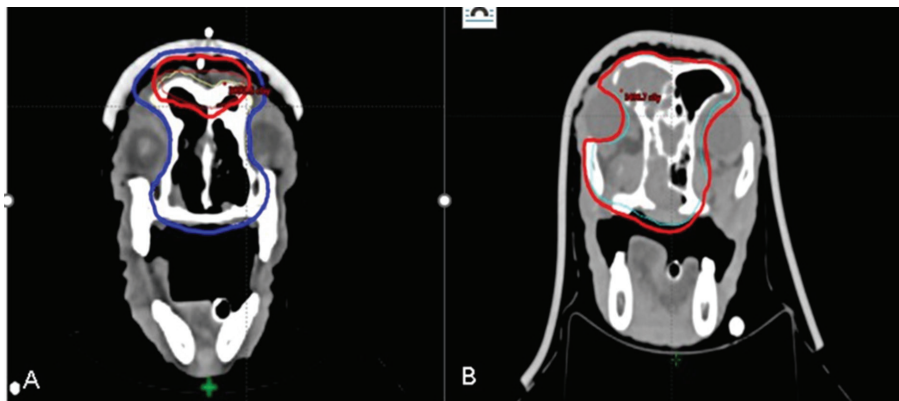


Fig 3. A) Dose of 35Gy/5Fr is given to GTV (red isodose line), while the dose prescribed to PTV created with CTV + 3 mm is 30Gy/5Fr (SIB) (dark blue isodose line), B) Dose prescribed to PTV volume created with CTV + 3 mm: 30 Gy/5Fr (red isodose line)

range (25th-75th percentiles), and frequency (number and percentage), as appropriate. The Fisher-Freeman-Halton exact test was used to evaluate associations between categorical variables. The relationship between age and survival was assessed using Spearman's rank correlation analysis.

Survival outcomes, including progression-free survival time (PFST), were compared between breeds and radiotherapy protocols using the log-rank (Mantel-Cox) test and Kaplan-Meier survival curves were generated. The likelihood ratio chi-square test was used to compare acute and chronic side effects between two groups. A two-sided P value <0.05 was considered statistically significant. All statistical analyses were performed using SPSS software (version 29.0).

RESULTS

A total of 12 dogs were included in the study. Breed distribution consisted of 6 Golden Retrievers, 3 Terriers, 1 Labrador Retriever, 1 Jack Russell Terrier, and 1 Setter. The mean age of the dogs was 9 years (range: 2-14 years), and the population included 6 males and 6 females. The primary tumor was located in the right nasal cavity in 5 dogs, the left nasal cavity in 6 dogs, and bilaterally in 1 dog. Common clinical signs included facial deformity (DE), dyspnea (DY), epistaxis (EP), nasal congestion (NC), sneezing (SN), and exophthalmos (EX).

Based on histopathological examination and CT evaluation, tumor types were identified as follows: 4 squamous cell carcinomas (SCC), 2 adenocarcinomas (ACA), 2 hemangiosarcomas (HSA), 1 transitional cell carcinoma (TCC), 1 malignant fibrous histiocytoma (MFH), and 2 undifferentiated neoplasms (UN). According to the modified Adams staging system, 1 case was classified as T1, 3 as T2, 5 as T3, 2 as T4, and 1 as T4a (Table 1; Fig. 4).

During the 450-day study period, 5 of the 12 dogs died: case N1 on day 150, N2 on day 105, N4 on day 440, N5 on day 40, and N12 on day 100. Cases N1 and N4 died due to multiple organ failure, whereas cases N2, N5, and N12 died as a result of respiratory failure.

During the planned follow-up period, the overall survival time (OST) and progression-free survival time (PFST) were 346 days and 238 days, respectively, for dogs treated with IG-HyVMAT. In dogs treated with the IG-HyVMAT SIB protocol, OST was 340 days and PFST was 238 days.

Case N6 exhibited a PFST of 304 days, whereas case N9 showed a PFST of 443 days, after which recurrence was detected on day 450, marking the end of the study. The owners of both dogs declined further treatment and could not be contacted for continued follow-up.

Seven dogs remained alive at the end of the follow-up period. Among these, three dogs (N9, N10, N11) had been

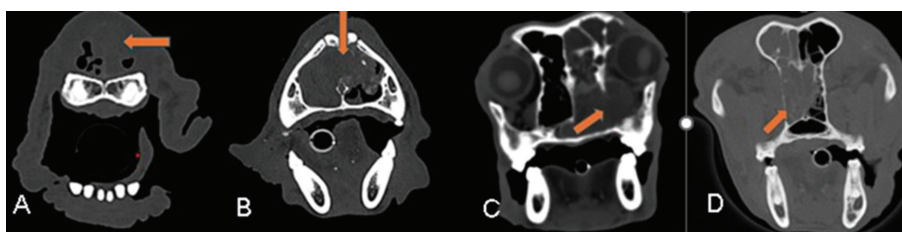


Fig 4. A) Stage 1, rostral mass involvement at N2 (arrow), B) Stage 2, nasal septum involvement at N3 (arrow), C) Stage 3, orbital involvement at N9 (arrow), D) Stage 4a, cribriform plate invasion at N10 (arrow)

treated with the IG-HyVMAT protocol, while four dogs (N3, N6, N7, N8) had received IG-HyVMAT SIB. The mean PFST among the seven surviving dogs was 312 days (Table 1).

Although a moderate negative correlation was observed between age and PFST, this relationship was not statistically significant ($r=-0.508$, $P=0.092$). Mortality rates were found to be significantly higher in Golden Retrievers and in dogs presenting with dyspnea (DY) and nasal congestion (NC). No significant association was detected between recurrence rates and the other evaluated variables.

Acute Toxicity

Early toxicity evaluations were performed in 10 cases. Regarding cutaneous toxicity, no findings were observed in one patient (G0), whereas three patients developed dry desquamation and alopecia (G1). Moist desquamation (G2) was observed in four patients, and edematous desquamation (G3) occurred in two patients. With respect to mucosal membranes, no early side effects were observed in eight patients (G0), while one patient developed G2 toxicity and another developed G3 toxicity (Fig. 5). According to VRTOG criteria, early ocular toxicities are defined as moderate conjunctivitis and scleral congestion (G1); keratoconjunctivitis sicca (KCS) requiring artificial tears, moderate conjunctivitis, and iridocyclitis requiring treatment (G2); and ulcerative keratitis with or without vision loss and glaucoma (G3). In this study, evaluation of early ocular side effects revealed no toxicity in four patients, moderate conjunctivitis (G1) in two patients, and KCS requiring artificial tears (G2) in four patients. These early side effects appeared during the second week following radiotherapy and resolved within approximately 1-1.5 months (Table 1).

Late Toxicity

Late toxicity evaluation was performed in 8 cases. All late adverse effects that developed after the third month following radiotherapy were considered permanent. Regarding cutaneous findings, no abnormalities were observed in two cases. Four dogs exhibited G1 toxicity (alopecia, hyperpigmentation, and leukotrichia),

while two dogs developed G2 toxicity characterized by symptomatic induration and fibrosis (Fig. 6). According to VRTOG parameters, late ocular toxicities in sinonasal tumor irradiation include asymptomatic cataracts or KCS (G1); symptomatic cataracts, keratitis, corneal ulceration, minor retinopathy, or moderate glaucoma (G2); and panophthalmitis, blindness, severe glaucoma, or retinal detachment (G3). In this study, five dogs showed no late ocular toxicity, while three dogs developed G2 toxicities. Ophthalmologic examinations revealed no G3-level adverse effects. Among the three dogs exhibiting G2 toxicity (N4, N6, N7), all had persistent KCS requiring ongoing supportive therapy, which had initially developed during the acute phase. In addition, cases N6 and N7 developed symptomatic right-sided cataracts with visual impairment, accompanied by bilateral keratitis, corneal ulceration, and descemetocele formation. None of the more severe ocular lesions that may occur at the G2 level, such as minor retinopathy or glaucoma, were observed. In case N7, bilateral limbal stem cell deficiency developed alongside cataract formation. Although this finding is not included in the VRTOG late toxicity scoring system, it was considered clinically significant. In the same patient, vision in the right eye was restored following extracapsular lens extraction (ECLE) using phacoemulsification, performed at the owner's request (Fig. 7).

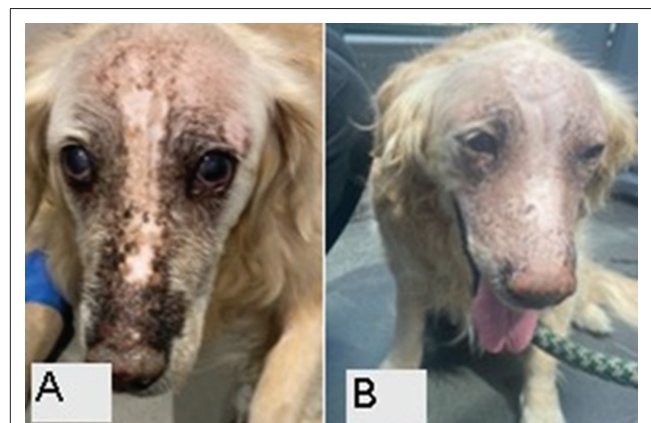


Fig 6. Late-stage skin toxicity. A) Alopecia, hyperpigmentation, leukotrichia (Grade 1), B) Asymptomatic induration/fibrosis (Grade 2)

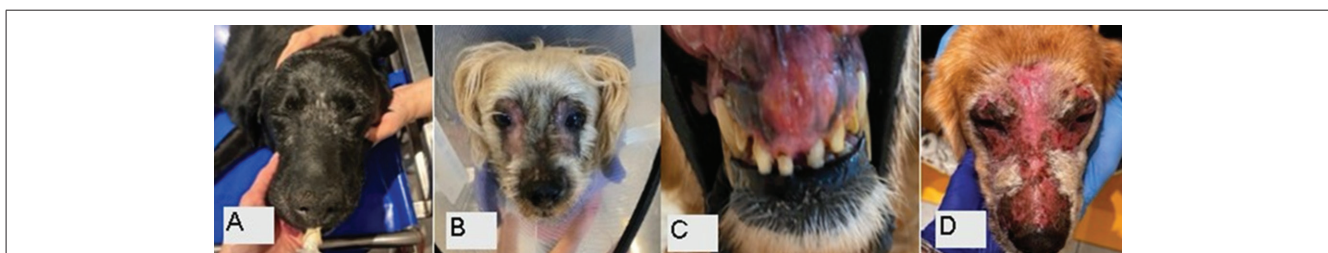

Fig 5. Early skin and mucous membrane toxicity. A) Erythema, dry desquamation, alopecia (Grade 1), B) Moist desquamation (Grade 2), C) Pachy mucositis (Grade 2), D) Confluent desquamation with edema (Grade 3)

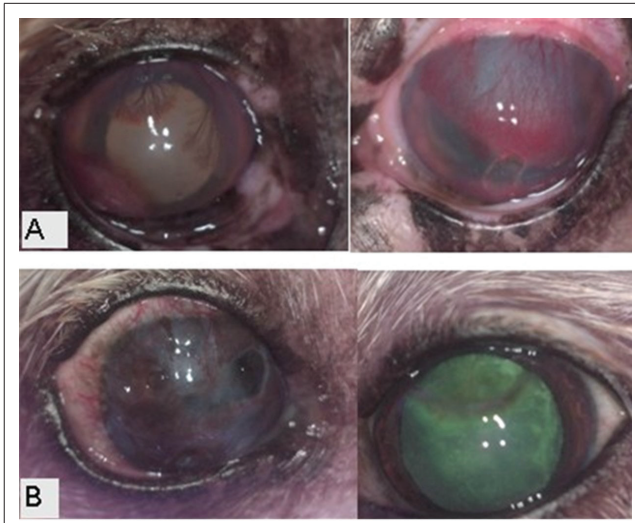


Fig 7. Late-stage ocular toxicity. A) Keratitis due to KCS (G1) and limbal stem cell insufficiency in both right and left eye (G2), B) Descemetocoele in the right eye, limbal stem cell insufficiency in both eyes (G2) and KCS (G1)

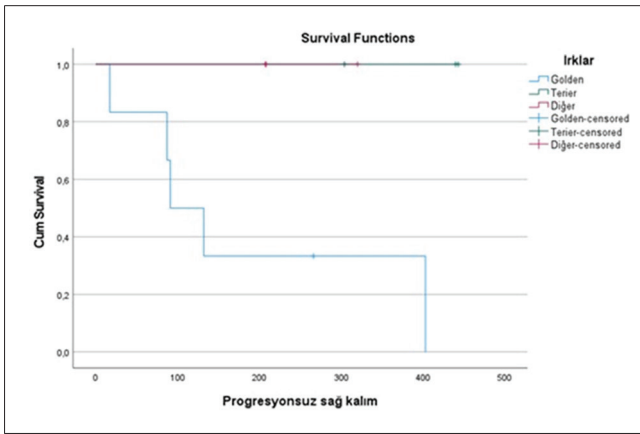


Fig 8. Kaplan-Meier curve for progression-free survival time in Golden Retrievers, Terriers, and other breeds

of acute side effects. However, significant differences were detected in chronic toxicities, particularly involving the skin ($P=0.020$) and ocular tissues ($P=0.049$) in dogs treated with IG-HyVMAT SIB (Table 1). Comparative analysis of PFST between breeds demonstrated a statistically significant difference ($\chi^2=7.51$, $P=0.028$). Golden Retrievers exhibited significantly shorter PFST compared with Terriers and other breeds (Fig. 8). No statistically significant difference in progression-free survival time (PFST) was observed between the IG-HyVMAT and IG-HyVMAT SIB groups ($\chi^2=0.002$, $P=0.964$). Follow-up CT examinations performed approximately 120 days after radiotherapy in dogs treated with IG-HyVMAT SIB generally demonstrated a marked reduction in gross tumor volume (GTV) (Fig. 9).

DISCUSSION

Adenocarcinomas are generally reported to be the most common histologic subtype in canine nasal tumors, followed by squamous cell carcinomas (SCCs) and, less frequently, chondrosarcomas. Other tumor types, including fibrosarcomas, osteosarcomas, and undifferentiated or anaplastic sarcomas, have also been described [2,11]. In a study evaluating radiotherapy outcomes in 166 dogs diagnosed with NLNT, a significant difference in survival time was demonstrated between adenocarcinoma and squamous cell carcinoma [13]. In contrast to those reports, SCCs were more common than adenocarcinomas in the present cohort. Nevertheless, our findings were consistent with previous data showing the overall predominance of carcinomas over sarcomas [2,14].

Nasal carcinomas have been reported most frequently in dolichocephalic breeds such as Golden Retrievers,

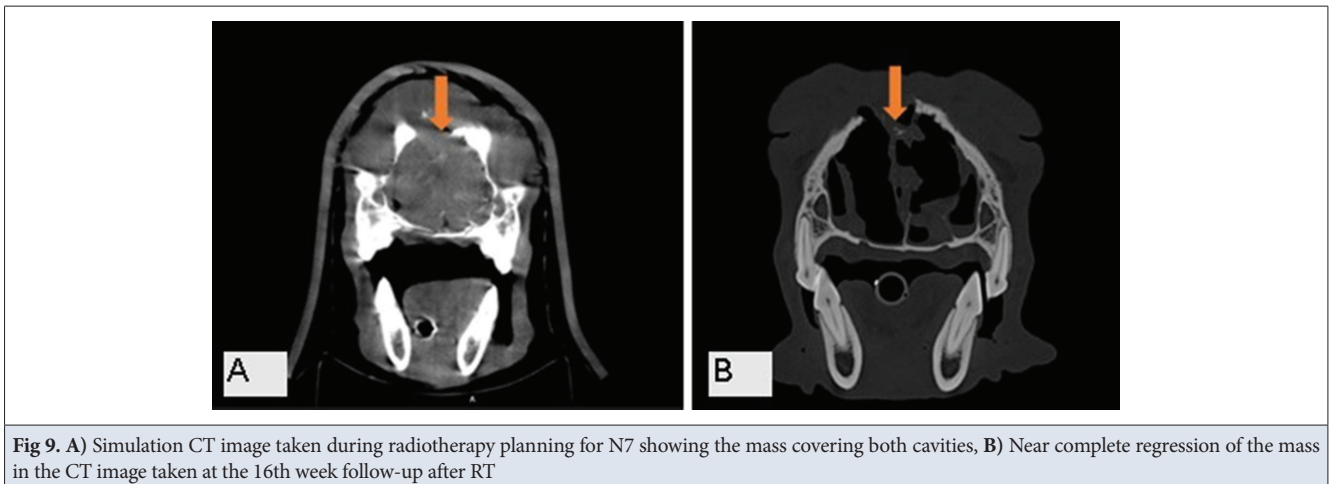


Fig 9. A) Simulation CT image taken during radiotherapy planning for N7 showing the mass covering both cavities, B) Near complete regression of the mass in the CT image taken at the 16th week follow-up after RT

Comparative Treatment Outcomes

No statistically significant difference was observed between the IG-HyVMAT and IG-HyVMAT SIB groups in terms

Labrador Retrievers, German Shepherd Dogs, and English Springer Spaniels, with a median age at diagnosis of approximately 10 years [2,14]. In the present study,

although a moderate negative correlation was observed between age and PFST, mortality was significantly higher in Golden Retrievers than in Terriers and other breeds. This finding suggests that breed-related differences may influence disease behavior or treatment response in ways not fully explained by current staging systems. Evaluation of tumor laterality revealed 5 right-sided, 6 left-sided, and 1 bilateral lesion, with no meaningful difference identified, suggesting that either side of the nasal cavity may be affected.

In linac-based hypofractionated stereotactic radiotherapy (SRT) studies for canine nasal tumors delivering a total dose of 30 Gy, overall survival time (OST) has been reported to range from 500 to 586 days, with minimal acute adverse effects [7,15]. Similarly, a study using SRT at a dose of 10 Gy \times 3 fractions in dogs with NLNT reported an OST of 745 days [9]. In another report including 182 dogs with NLNT treated with 10 Gy \times 3 fractions, OST was 441 days and acute morbidity was minimal [1]. In dogs with NLNT treated with either 3 consecutive fractions of 9–10 Gy or a single fraction of 20 Gy SRT, OST was reported as 388 days [8]. Another study in 129 dogs with NLNT treated with 10 Gy \times 3 fractions reported clinical improvement with minimal acute toxicity and an OST of 542 days [10].

In cases diagnosed with stage 4 nasal carcinoma, characterized by cribriform plate lysis and adjacent bone lysis extending into the intracranial region, SRT was delivered at a total dose of 30–35 Gy in 3–5 sessions (7–10 Gy per fraction), and recurrence was observed 3 to 5 months later, with an OST of 170 days [11]. In another study, 88% of dogs with NLNT treated with SRT derived clinical benefit, with a PFST of 359 days and an OST of 563 days [15].

Considering the small number of cases included in our study, the limited follow-up period for evaluating early findings, and the fact that 7 of 12 dogs were still alive on day 450, our overall apparent success rate was 58%. We considered the mean PFST of the 7 dogs that remained alive throughout the 450-day follow-up period (312 days) to be clinically relevant, and this finding was consistent with the PFST of 359 days reported by Fox-Alvarez et al. [15].

The SIB technique is considered important because it combines the advantages of dose escalation and fractionation by delivering different dose levels to different target volumes within the same treatment course. In a study of 49 dogs with NLNT, 27 dogs received conventional SRT (10 \times 4.2 Gy), whereas 22 dogs were treated with an SIB protocol (10 \times 4.83 Gy to the gross tumor). The mean PFST was 274 days for the conventional protocol and 300 days for the SIB protocol. Although the SIB protocol was reported to be positively associated with prognosis, the difference between groups was not statistically significant [16].

In the present study, IG-HyVMAT, predominantly applied with SIB, was prescribed at doses ranging from 25 to 40 Gy. In dogs treated with IG-HyVMAT, OST and PFST were 346 and 238 days, respectively, and 60% survived today 450. In dogs treated with IG-HyVMAT SIB, OST and PFST were 340 and 238 days, respectively, and 57% survived today 450. These treatment regimens were well tolerated and associated with minimal acute toxicity. Although the small sample size and presence of censored cases limit definitive conclusions, the achievement of meaningful survival times with minimal acute toxicity in dogs treated with SIB supports further investigation of this approach. On the other hand, tumor size and location also appeared to be major factors influencing the clinician's decision regarding dose escalation and the extent of organ-at-risk sparing.

An et al. [11] reported three dogs presented with epistaxis and facial deformity in which CT demonstrated soft tissue-attenuating, contrast-enhancing masses involving both nasal cavities, together with cribriform plate lysis and adjacent bone lysis extending intracranially. These cases were diagnosed as stage 4 nasal carcinoma and treated with radiotherapy at a total dose of 30–35 Gy over 3–5 sessions (7–10 Gy per fraction). Monthly follow-up CT examinations showed tumor shrinkage after treatment, although recurrence was observed 3 to 5 months later, and the mean OST was 170 days. The authors concluded that SRT provided treatment precision even in dogs with nasal carcinoma and cribriform plate lysis without causing severe radiation toxicity. They recommended follow-up CT evaluations at 1, 3, and 6 months after SRT for prognostic assessment and recurrence monitoring. Clinical signs initially observed in dogs with nasal tumors include epistaxis, mucopurulent nasal discharge, facial deformity, sneezing, stertorous breathing, dyspnea, ocular discharge, and, in advanced cases, neurologic signs associated with cribriform plate invasion.

In the present study, one case with T4-stage cribriform plate destruction died on day 150, whereas another case with T4a-stage brain invasion was still alive at the end of follow-up; therefore, no clear conclusion could be drawn regarding the prognostic significance of these findings. No neurologic deficits or fistula formation were encountered, including in the dog with cribriform plate lysis, although other common clinical signs were observed. This suggests that radiologic invasion may not necessarily be associated with neurologic dysfunction. However, the significantly higher mortality observed in dogs presenting with dyspnea (DY) and nasal congestion (NC) suggests that these clinical signs may reflect more advanced local disease and may serve as additional prognostic indicators.

It is well established that OST in dogs with NLNT treated with SRT ranges from 10 to 19 months (300–540 days) [3,4].

In the present study, OST was 346 days in dogs treated with IG-HyVMAT and 340 days in those treated with IG-HyVMAT SIB, further supporting the clinical effectiveness of radiotherapy. Comparative analysis of PFST between breeds revealed a statistically significant difference, with Golden Retrievers demonstrating significantly shorter PFST than Terriers and other breeds. This may be associated with the shorter survival observed in this breed. Earlier mortality in Golden Retrievers may also have limited the observation period during which recurrence could be detected, suggesting the possibility of survival-related bias in breed-based comparisons of recurrence.

Although no significant difference in PFST was observed between the IG-HyVMAT and IG-HyVMAT SIB groups, follow-up CT examinations performed on day 120 after radiotherapy in the IG-HyVMAT SIB group generally demonstrated a marked reduction in gross tumor volume (GTV). This finding supports further investigation of this protocol, particularly in cases where GTV is substantial and the primary aim is to achieve improved local palliation.

In the present study, acute side effects resolved within 1 to 1.5 months, while chronic adverse effects included permanent alopecia and hyperpigmentation (G1) in four cases and asymptomatic induration/fibrosis (G2) in one case, none of which appeared to negatively affect patient quality of life. In addition, permanent KCS of G1 severity was observed in four dogs, and G2 symptomatic cataract and keratitis were observed in three dogs, whereas other adverse effects such as retinopathy, glaucoma, and permanent blindness were not encountered. Furthermore, restoration of vision in the right eye of one dog with cataract following extracapsular lens extraction suggested that these adverse effects did not severely compromise patient comfort and also contributed to owner satisfaction. In contrast, limbal stem cell deficiency observed in two cases, although not included in the VRTOG toxicity scoring system, suggests that this entity should also be considered in ophthalmologic assessments of late morbidity. These findings support the importance of lacrimal gland and corneal dose constraints as reported by Poirier et al.^[17]. Our observations regarding early and late radiotherapy-related morbidity were also consistent with the toxicities described by Mortier and Blackwood^[2].

Although no significant difference in acute adverse effects was observed between dogs treated with IG-HyVMAT and those treated with IG-HyVMAT SIB, significant differences in chronic skin and ocular toxicities were observed in the SIB-treated group. This finding may be attributable to the higher doses delivered within the planned target volume (PTV) in dogs receiving SIB.

Radiation-induced visual impairment has been shown to be dose-dependent; mean ocular doses of approximately

39 Gy have been associated with vision loss, whereas doses below 30 Gy are generally reported to preserve visual function^[18]. In hypofractionated IMRT protocols, radiation-induced KCS represents a clinically important late complication, and a retrospective case-control study identified a corneal dose threshold of 14.9 Gy predictive of KCS development in dogs treated with large fraction sizes^[19].

In the present study, the mean lacrimal gland dose in cases that developed cataract and KCS approached 29 Gy, which was consistent with previous reports. Notably, the mean lacrimal gland doses in this study were approximately 19 Gy on both sides, and permanent KCS occurred only in dogs receiving doses near the upper end of the reported range. This observation supports the concept that tumor proximity to ocular structures, and the resulting unavoidable dose escalation, plays a critical role in the development of late ocular toxicity. Consistent with previous IMRT planning studies, these findings reinforce the importance of lacrimal gland contouring and the application of conservative dose constraints, particularly when hypofractionated SRT protocols are used. Vision-threatening complications involving the lens, retina, or optic nerve were rare in our study, with only three dogs developing G2 ocular toxicity. These findings emphasize the importance of careful dose planning for ocular structures, particularly the corneal limbus and lacrimal gland, in order to minimize the risk of permanent KCS and stem cell deficiency. Although symptomatic treatment provided clinical improvement, these complications underscore the need for stricter dose constraints in hypofractionated SRT protocols.

Because there is no standardized radiotherapy protocol for canine nasal tumors, further studies with larger case numbers, longer follow-up periods, and more detailed reporting of early and late toxicities are needed. The results of the present study, conducted in a veterinary hospital setting in Türkiye using an officially authorized and legally established certified radiotherapy device and a multidisciplinary team including a veterinary oncology specialist and a medical physicist from the same institution, support the use of IG-HyVMAT as an effective treatment modality capable of providing meaningful survival benefits with an acceptable toxicity profile.

In conclusion, our findings were consistent with previously published studies in terms of OST, PFST, toxicity, and dose parameters. Radiotherapy appeared to increase PFST and OST with minimal adverse effects. Future research should focus not only on PFST, OST, and toxicity grading according to VRTOG criteria, but also on SIB-based treatment planning strategies in which dose constraints for adjacent functionally critical organs, particularly the lacrimal gland and corneal structures, are carefully evaluated.

DECLARATIONS

Availability of Data and Materials: All data generated or analyzed during this study are available from the corresponding author (Ö. K.) upon reasonable request.

Acknowledgements: The authors would like to thank all staff members of the VetAmerikan Animal Hospital Radiotherapy Unit for their support during the study.

Financial Support: This research received no specific grant from any funding agency.

Conflict of Interest: The authors declare no conflicts of interest.

Declaration of Generative Artificial Intelligence (AI): This manuscript (including tables and figures) was not written using generative artificial intelligence or AI-assisted technologies.

Author Contributions: Data collection, study execution, and analysis: OÜ, EEÇ, VA, EO, US, YB, AD; manuscript preparation: FEÖ, EEÇ, ÖK, VA, YB; critical review: OÜ, YB, US, EO, FEÖ, APG. All authors have read and approved the final manuscript and agree to take responsibility for all aspects of the work. This statement complies with the journal's "Ethical Principles and Publication Policy / Authorship and Author Rights" guidelines.

REFERENCES

1. **Yoshikawa H, Lafferty MH, Griffin LR, LaRue SM:** A retrospective study of sinonasal tumors in 182 dogs treated with stereotactic radiotherapy (3 × 10 Gy) (2010–2015). *J Vet Intern Med*, 37, 2356-2367, 2023. DOI: 10.1111/jvim.16838
2. **Mortier JR, Blackwood L:** Treatment of nasal tumours in dogs: A review. *J Small Anim Pract*, 61, 404-415, 2020. DOI: 10.1111/jsap.13173
3. **Woodruff MJ, Heading KL, Bennett P:** Canine intranasal tumours treated with alternating carboplatin and doxorubicin in conjunction with oral piroxicam: 29 cases. *Vet Comp Oncol*, 17 (1): 42-48, 2019. DOI: 10.1111/vco.12443
4. **Stevens A, Turek M, Vail D, Christensen N, Forrest L:** Definitive-intent intensity-modulated radiotherapy for modified-Adams stage 4 canine sinonasal cancer: A retrospective study of 29 cases (2011–2017). *Vet Radiol Ultrasound*, 61, 718-725, 2020. DOI: 10.1111/vru.12899
5. **Fujiwara A, Kobayashi T, Kazato Y, Yayoshi N, Fujita M:** Efficacy of hypofractionated radiotherapy for nasal tumours in 38 dogs (2005–2008). *J Small Anim Pract*, 54, 80-86, 2013. DOI: 10.1111/jsap.12024
6. **Tollett MA, Duda L, Brown DC, Krick EL:** Palliative radiation therapy for solid tumors in dogs: 103 cases (2007–2011). *J Am Vet Med Assoc*, 248, 72-82, 2016. DOI: 10.2460/javma.248.1.72
7. **Gieger TL, Nolan MW:** Linac-based stereotactic radiation therapy for canine non-lymphomatous nasal tumours: 29 cases (2013–2016). *Vet Comp Oncol*, 16, E68-E75, 2017. DOI: 10.1111/vco.12334
8. **Mayer MN, DeWalt JO, Sidhu N, Mauldin GN, Waldner CL:** Outcomes and adverse effects associated with stereotactic body radiation therapy in dogs with nasal tumors: 28 cases (2011–2016). *J Am Vet Med Assoc*, 254 (5): 602–609, 2019. DOI: 10.2460/javma.254.5.602
9. **Gieger TL, Haney SM, Nolan MW:** Re-irradiation of canine non-lymphomatous nasal tumours using stereotactic radiation therapy (10 Gy × 3) for both courses: 11 dogs. *Vet Comp Oncol*, 20, 502–508, 2022. DOI: 10.1111/vco.12801
10. **Nolan MW, Berman AR, Watson-Skaggs ML, Quinn CN, Marcus KL, Russell K, Yoshikawa H, Olby NJ, Gieger TL:** Stereotactic radiotherapy (10 Gy × 3) for canine nonlymphomatous intranasal tumors is associated with prolonged survival and minimal risk of severe radiotoxicity. *J Am Vet Med Assoc*, 260 (12): 1496–1506, 2022. DOI: 10.2460/javma.22.03.0141
11. **An SY, Hwang GH, Choi MY, Huh C, Yoon YM, Lee HC, Hwang TS:** Stereotactic radiation therapy for nasal carcinoma with cribriform plate destruction in three dogs: A Serial CT study. *J Vet Clin*, 40 (2): 139–146, 2023. DOI: 10.17555/jvc.2023.40.2.139
12. **Vanhaezebrouck IF, Scarpelli ML:** Companion animals as a key to success for translating radiation therapy research into the clinic. *Cancers*, 15:3377, 2023. DOI: 10.3390/cancers15133377
13. **Mizuno R:** Prognostic factors and survival following radiation therapy for canine nasal tumors: A single-institution retrospective study of 166 cases. *Open Vet J*, 14 (7): 1538–1552, 2024. DOI: 10.5455/OVJ.2024.v14.i7.3
14. **Sones E, Smith A, Schleis S, Brawner W, Almond G, Taylor K, Haney S, Wypij J, Keyerleber M, Arthur J, Hamilton T, Lawrence J, Gieger T, Sellon R, Wright Z:** Survival times for canine intranasal sarcomas treated with radiation therapy: 86 cases (1996–2011). *Vet Radiol Ultrasound*, 54 (2): 194–201, 2013. DOI: 10.1111/vru.120062
15. **Fox-Alvarez S, Shiomitsu K, Lejeune AT, Szivek A, Kubicek L:** Outcome of intensity-modulated radiation therapy-based stereotactic radiation therapy for treatment of canine nasal carcinomas. *Vet Radiol Ultrasound*, 61, 370–378, 2020. DOI: 10.1111/vru.12854
16. **Meier V, Staudinger C, Körner M, Soukup A, Rohrer Bley C:** Dose-escalated simultaneously integrated boost radiation protocol fails to result in a survival advantage for sinonasal tumors in dogs. *Vet Radiol Ultrasound*, 63, 633–648, 2022. DOI: 10.1111/vru.13086
17. **Poirier VJ, Matsuyama A, Kim C, Darko J, Fleck A:** Clinical-dosimetric relationship between lacrimal gland dose and keratoconjunctivitis sicca in dogs with sinonasal tumors treated with radiation therapy. *J Vet Intern Med*, 34 (2): 867–872, 2020. DOI: 10.1111/jvim.15744
18. **Wolf F, Meier VS, Pot SA, Rohrer Bley C:** Ocular and periocular radiation toxicity in dogs treated for sinonasal tumors: A critical review. *Vet Ophthalmol*, 23 (4): 596–610, 2020. DOI: 10.1111/vop.12761
19. **Ohnishi A, Takeda S, Okada Y, Tokoro M, Kageyama S, Itoh Y, Asanuma T:** Risk factors for radiation-induced keratoconjunctivitis sicca in dogs treated with hypofractionated IMRT for intranasal tumors. *Animals (Basel)*, 15 (15):2258, 2025. DOI: 10.3390/ani15152258